

Application of Lasers for Soft Tissues in Orthodontic Treatment: A Narrative Review

Sarah Ahmed Al-Twajiri¹, Ghada H. AlKharboush¹, Maryam Abdullah Alohali¹, Israa Faisal Arab¹, Roba Hassan Alqarni^{1*}, Mawahib Samhoud Alharbi²

¹Department of Orthodontics, Prince Sultan Military Medical City, Riyadh.

²Department of Advanced Education in General Dentistry, Prince Sultan Military Medical City, Riyadh.

Abstract

Orthodontics has recently used lasers for a broad range of operations. Beyond the previously indicated spectrum of treatments, lasers have emerged as a valuable tool for many soft tissue procedures, replacing traditional scalpel-based techniques in managing soft tissue during orthodontic treatments. Owing to the need for more available data on the latter topic, this research was structured to include clinical studies using laser-assisted soft tissue ablation in orthodontics. Five years (2010-2015) with a limitation on the use of the English language and clinical trial design were used to search the literature using the PubMed and Google Scholar databases. The authors retrieved research that used a laser to apply soft tissue during orthodontic therapy. A mere eight studies satisfied the inclusion requirements. Regarding the result of the therapy, there was no discernible difference between laser ablation and traditional scalpel techniques. There were still some questions, however, about how the previously outlined processes differed. In conclusion, if there has been less bleeding and pain during the surgical operation, laser performance might be advised. Clinical applications of scalpel-based surgery in the cosmetic area with bracket-bonded teeth are yet unclear. It is crucial to exercise care and be knowledgeable about the properties of laser beams, including their wavelength, frequency, power, and timing.

Keywords: Laser AND surgical uncovering, Gingival hyperplasia, Gingival hypertrophy, Randomized control trial

Corresponding author: Roba Hassan Alqarni

E-mail ✉ Dentist.roba@hotmail.com

This is an open access journal, and articles are distributed under the terms of the Creative Commons Attribution-Non Commercial-ShareAlike 4.0 License, which allows others to remix, tweak, and build upon the work non-commercially, as long as appropriate credit is given and the new creations are licensed under the identical terms.

How to Cite This Article: Al-Twajiri SA, AlKharboush GH, Alohali MA, Arab IF, Alqarni RH, Alharbi MS. Application of Lasers for Soft Tissues in Orthodontic Treatment: A Narrative Review. Bull Pioneer Res Med Clin Sci. 2024;3(1):1-6.

Introduction

A laser is a kind of light wavelength that concentrates energy by passing through a collimated tube. Light is the following explanation for this energy. One may create laser irradiation using a variety of elements found in the periodic table. Various laser systems can emit either visible or invisible light. Theodore H. Maiman introduced the first visible light-emitting laser. Invisible beams emit lasers at a distinct spectrum in the ultraviolet and infrared regions, whereas visible beams produce lasers at 400–780 nm. Property classifications for lasers include wavelength,

type, output power, and emission type (pulsed or continuous). Diverse uses may arise from variations in irradiation characteristics. A laser's classification may be based on its wavelength (390-700 nm), material of lasing (solid or gas), and tissue applicability (soft and hard tissue) [1].

In dentistry, lasers have a wide range of indications based on distinct properties. These include pain alleviation, gingival depigmentation, complex tissue ablation, soft tissue removal, and nonsurgical sulcular debridement. Laser therapy has been the subject of several research studies as an auxiliary method in orthodontic practice.

Numerous benefits of laser therapy have impacted orthodontic procedures, including soft tissue excision, debonding ceramic brackets, and quickening tooth movement. When it comes to soft tissue surgery, a laser is more advantageous than a scalpel. It removes postoperative sutures, sterilizes the target region, and coagulates blood vessels. Studies have shown a decrease in analgesic and local anesthetic medication consumption during laser surgery, as well as a decrease in postoperative pain and discomfort.

Nevertheless, there are still several drawbacks to orthodontic adjunctive laser therapy. The expensive cost of laser devices limits the application of lasers. The tactile feeling of the scalpel is another reason why some doctors like it. A further problem with inexperienced operators is soft tissue ablation. Insufficient operational expertise might expose bones and cause significant heat injury to the tissue. According to several research studies, there is no difference between laser and traditional scalpel procedures [2, 3].

Erbium and diode lasers are popular kinds of lasers used in soft tissue applications. It is possible to do hard tissue or soft tissue surgery using the various wavelengths and input powers of lasers. They are nearly usually employed for soft tissue ablation. Less hard tissue damage from diode lasers results from this feature because diode lasers have a high absorption in soft tissue and a low absorption in bone and other hard tissues.

Yttrium aluminum garnet (Er: YAG), doped with erbium, is the most widely used erbium laser material. Erbium lasers have a much more comprehensive wavelength range (2780–2940 nm) than diode lasers (810–980 nm). Both complex tissue ablation and absorption by hydroxyapatite

are possible. Compared to an erbium laser, a diode laser needs less power input for soft tissue excision [4, 5].

Numerous research investigations have examined the potential applications of laser-assisted soft tissue ablation in orthodontic treatments in recent years. Gingivectomy, fibrotomy, frenal excision, surgical uncovering, and gingival hypertrophy/hyperplasia removal are common goals. The majority of studies are case reports or case series with small sample sizes, making it impossible to compare laser with more conventional methods.

Materials and Methods

This study aimed to gather sufficient research on publications from 2010 to 2015 from the PubMed and Google Scholar databases. Gingivectomy, lingual frenum, labial frenum, "soft tissue AND orthodontics," "laser AND surgical uncovering," "gingival hyperplasia," and "gingival hypertrophy" were among the keywords derived from MeSH terms. The studies that met the eligibility criteria for this review were as follows: (1) Complete text available in English; (2) prospective randomized and non-randomized clinical trials; and (3) human subjects-only research.

Two distinct writers carried out the data extraction after doing separate analyses of the search. Eight out of the 97 articles met the requirements for the final analysis based on the PRISMA diagram. **Figure 1** displays the clinical trial selection flowchart diagram. Extracted for every study were the following: year of publication, number of patients overall, age distribution, kind of laser evaluation, treatment indications, experimental and control groups, and conclusion.

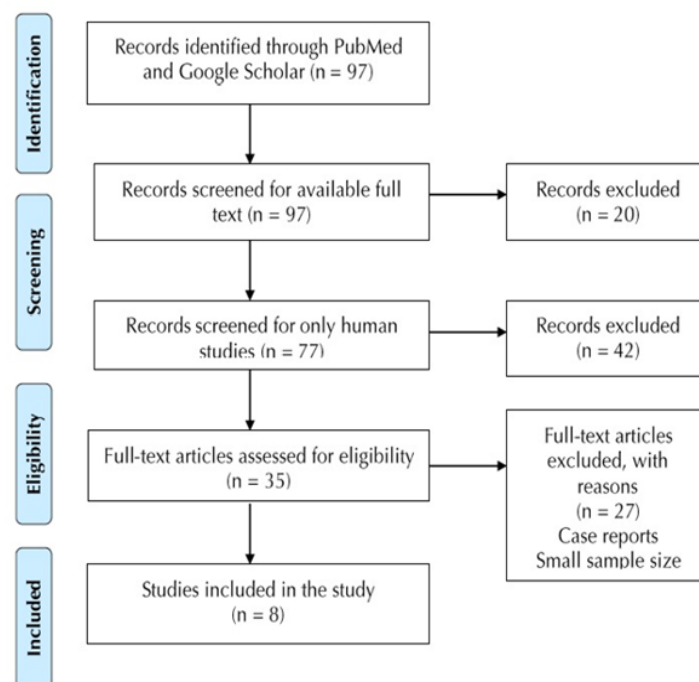


Figure 1. The Flowchart Diagram of Selected Clinical Trials.

Results and Discussion

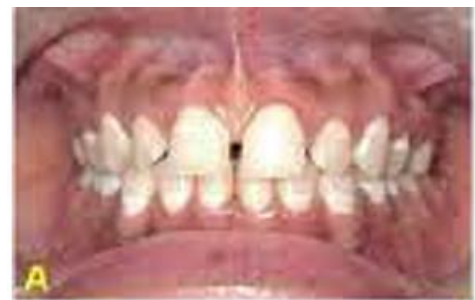We included eight papers in this review. The age range of the patients was 10 to 32. The table provides an overview of the clinical studies that were part of this investigation. Two studies reported labial frenectomy, while four research employed lasers for gingivectomy (**Figures 3 and 4**). Two publications looked into lingual frenectomy. Seifi *et al.* and Ize-Iyamu *et al.* performed surgical exposure of delayed tooth eruption. A study that contrasted the use of a laser with a traditional scalpel approach for fiberotomy found that the use of a laser in conjunction with fiberotomy effectively reduced rotational relapse. One patient had laser operculectomy in a different research. Six investigations made use of diode lasers. When compared to a traditional surgical method, Junior *et al.* used a neodymium-doped yttrium aluminum garnet (Nd: YAG) laser for a labial frenectomy. Jahanbin *et al.* performed fiberotomy using an Er: YAG laser. In lingual frenectomy, Aras *et al.* examined the effectiveness of Er: YAG and diode lasers. While the majority of articles used diode lasers in their processes, there are variations in the features of irradiated diode lasers only in terms of wavelengths and laser input strength.

For the goal of eliminating soft tissue in orthodontics, there was no discernible difference in treatment results between traditional surgical procedures and surgical laser intervention. A laser is a valuable tool for improving hemostasis, minimizing anesthetic penetration, reducing bleeding during procedures, and avoiding suturing. According to several research studies, laser surgery reduces postoperative discomfort. In four trials, laser groups were the only recipients of topical anesthetic. The author did not specify the number of patients who received the injection of local anesthesia, but Aboelsaad and Attia employed topical anesthetic gel and administered it as necessary. All patients in two publications received local infiltration and topical anesthetic. Jahanbin *et al.* [6] entered the target region via infiltration. When treating tongue ties, Aras *et al.* [7] used a laser without first applying a local anesthetic and compared the diode and Er: YAG lasers. This research included sixteen participants to assess if conducting lingual frenectomy without local anesthetic is acceptable. On the other hand, six out of the eight patients in the Er: YAG group did not need any local anesthetic at all during the surgery, while six patients in the diode laser group did.

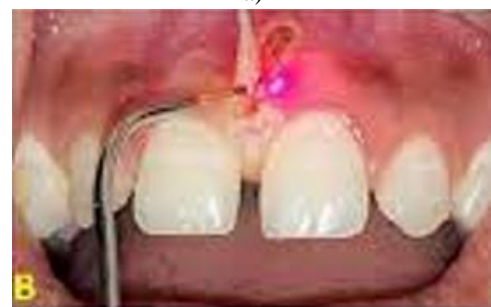The use of diode laser as a supplement to orthodontic therapy was proposed by Seifi *et al.* [8] The research comprised 16 individuals with delayed eruption of the second premolar. Using laser radiation, eight patients underwent surgical uncovering. The therapy resulted in satisfactory gingival condition and retained biological width. The results demonstrated a substantial acceleration in tooth eruption with laser intervention.

To *et al.* [9] conducted research in which they contrasted nonsurgical periodontal therapy with adjunctive diode laser gingivectomy in individuals who had fixed orthodontic appliances. Only early in the course of treatment did the experimental and control groups vary significantly, with the laser group demonstrating a marked improvement in periodontal health. The findings suggest that diode laser gingivectomy might lead to improved periodontal health sooner.

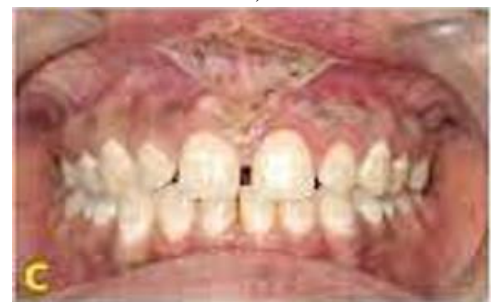Ize-Iyamu *et al.* [10] conducted research in which 23 patients had various soft tissue surgeries, including operculectomy, gingivectomy, frenectomy, and surgical exposure. The research above did not concentrate on a particular laser indication for treatments of soft tissues. Out of 23 patients, 12 had soft tissue laser intervention. In the diode laser group, there was a considerable decrease in postoperative discomfort and bleeding. According to the findings, only two procedures in the diode laser group needed anesthetic infiltration. Procedure time did not differ significantly between the laser and conventional groups.



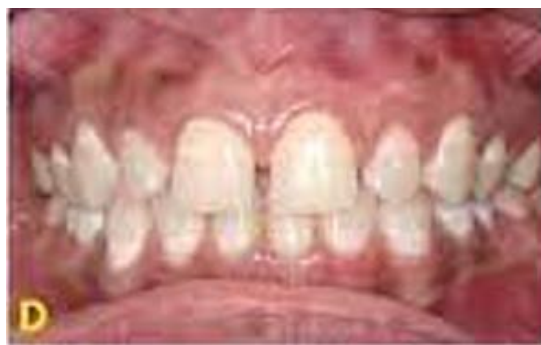a)



b)



c)



d)

Figure 2. frenectomy with soft laser

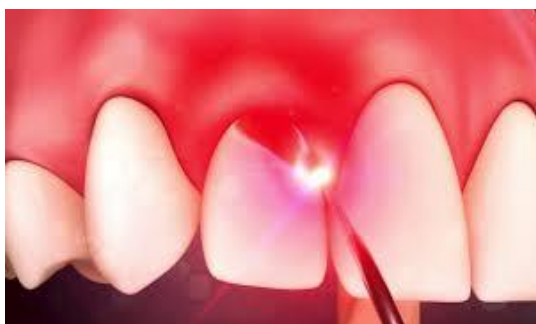
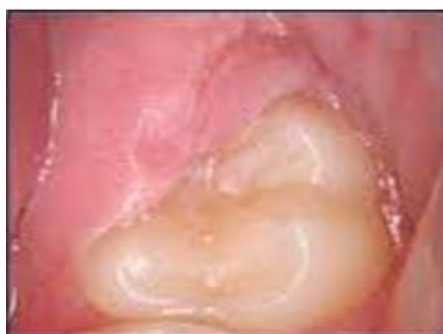
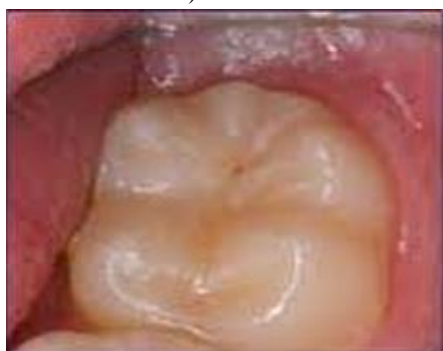Figure 3. Gingivectomy with soft laser



a) Before



b) After

Figure 4. Operculectomy with soft lasers

When orthodontic treatments caused hyperplastic gingivae, Aboelsaad and Attia [11] used a diode laser to cure them. Thirty-eight participants were used in this research to treat gingival hypertrophy; they were split into two groups: one for nonsurgical periodontal therapy and the other for laser treatment. The two groups' periodontal health did not significantly vary from one another.

However, the laser group's enhanced periodontal metrics were more noticeable in the early stages.

In research by Sobouti *et al.* [12] thirty patients had treatment with the recommendation of an aesthetic-only gingivectomy in the anterior maxilla area. Fifteen patients had diode laser-aided surgery, while the control group underwent traditional scalpel surgery. The experimental group did not experience any discomfort during surgery, and the laser group's bleeding rate was considerably reduced. The research recommended using lasers to treat individuals undergoing cosmetic smile lift procedures.

Junior *et al.* [13] contrasted traditional labial frenectomy surgery with the Nd: YAG laser. Among 40 patients, this research found no discernible difference in postoperative pain or oral function between the groups using the scalpel approach and the laser group. There were variations in the duration of surgical therapy and transoperative bleeding, with the laser group exhibiting shorter recovery times. The absence of sutures was another benefit of laser use (**Figure 2**).

Research by Jahanbin *et al.* [6] examined the effectiveness of conventional circumferential suprarenal fiberotomy (CSF) and laser-assisted CSF in minimizing the recurrence of corrected orthodontic rotation. This research comprised twenty-four individuals who were nearing the end of their orthodontic treatment. Using an Er: YAG laser (Smart 2940D; Deka Laser, Florence, Italy; 2940 nm, 100 mJ energy), six patients underwent laser-aided CSF. Using images captured from dental models, the degree of relapse was computed one month later. There was no discernible difference in the amount of relapse between the laser group and the traditional CSF approach. Nonetheless, it was determined that the typical CSF group had more discomfort.

Research into laser-assisted orthodontic treatments has grown in the last few years. Clinical research contrasting various laser irradiation techniques alone or in conjunction with traditional surgical methods is relatively uncommon. The complexity of organizing a clinical study and the absence need of more samples covered in the criteria account for the small number of references [14, 15].

In the clinical studies we looked at, diode lasers were the most often employed kind of laser. Due to its minimal absorption by teeth and bone, diode lasers are suitable for soft tissue ablation. They provide a lesser risk of damaging the hard tissue underneath the targeted soft tissue, making the process safer. Gingivectomy, hyperplastic and inflammatory soft tissue removal, gingival exposure of impacted teeth, and frenal separation are among the several procedures performed using a diode laser. Studies, however, used a range of tip sizes, input powers, and wavelengths. We were unable to confirm the precise wavelength or other characteristics that may be added for various reasons based on current clinical research [16, 17].

Instead of the well-known diode laser, Junior *et al.* employed a Nd: YAG laser. The cutting and coagulation of soft tissue has been successful using Nd: YAG. During the process, it offers hemostasis and clear tissue visualization. Specimens from histopathology demonstrated less tissue damage and improved incision quality at higher frequencies and lower input powers. Diode lasers, on the other hand, also proved helpful in removing soft tissue. Aras *et al.* published a comparison of Er: YAG and diode lasers. The results showed that local anesthetic injection was not necessary to execute Er: YAG. Because of this feature, it may be more beneficial than the use of diode lasers, particularly in pediatric dentistry.

Nonetheless, the current study's author recommended using local anesthetic injection in some situations, such as surgical exposure. In addition to estimating the quantity of tissue that needed to be removed, the needling revealed the depth of soft tissue covering the crown of the delayed-erupted tooth, preventing thermal injury of the laser tip over the tooth to underlying tissues.

The majority of papers have either used topical anesthetic before or instead of local anesthetic. Different kinds of topical anesthetic medications exist, nevertheless [18-20]. In contrast to Seifi *et al.*, To *et al.* and Sobouti *et al.* who administered tetracaine-adrenaline-cocaine, or TAC 20% (lidocaine 20%, tetracaine 4%, and phenylephrine 2%), Junior *et al.* and Aboelsaad and Attia [9] employed benzocaine 20%. The kind of topical anesthetic that was used was left out by other writers. Compounded topical anesthetic gels, such as TAC and lidocaine, prilocaine, tetracaine, and phenylephrine with thickeners (profound PET), are necessary to provide sufficient soft tissue anesthesia for laser incision. The use of topical anesthetic gels for laser incisions without first administering a local anesthetic infusion is unproven. According to Junior *et al.* lengthy, thick frenums that show gingival, papillary, or transpapillary insertion are indicative of local infiltration. As a result, choosing the kind of anesthetic also involves considering the procedure's region. Therefore, the anesthetic level in the tissue that topical gels may achieve—which requires application before an infiltration technique—is insufficient. If a local anesthetic injection is not necessary for the use of Er: YAG or Nd: YAG, this is still up for debate. Er: The strong absorption of YAG lasers by water and mineral apatite is another feature that makes them useful for soft tissue ablation. It is best not to use it near teeth or bones since certain studies have shown instances of bone exposure [21-23]. This kind of laser has a greater risk of thermal injury to hard tissue during operations like labial frenectomy next to the papillary area, anterior maxilla cosmetic gingivectomy, or surgical exposure of a delayed-erupted tooth. It is essential to use lasers with lower absorption in water and hard tissue minerals in aesthetic regions when applying them to the

conditions above. Such lasers are more appropriate for the treatment of ankyloglossia. Another significant issue during laser irradiation is the operator's expertise and attention span [23-25]. The doctor must refrain from irradiating the periosteum or bone structure using lasers. Research is required to demonstrate the effectiveness of various laser types by contrasting Nd: YAG and Er: YAG lasers with diode lasers.

Conclusion

Most orthodontic research conducted in the last few years has focused on applying lasers. Nonetheless, there are still debates over the use of lasers in soft tissue procedures and how they compare to traditional scalpel techniques. Further investigation and clinical studies are required to introduce an appropriate laser with the correct wavelength, input power, and other characteristics for the indicated purposes. Even with today's cutting-edge technology, some medical professionals still choose traditional knife techniques for laser-assisted surgery. Future research should compare the costs and possible advantages of lasers.

Acknowledgments: None

Conflict of interest: None

Financial support: None

Ethics statement: None

References

1. Ahmed A, Fida M, Javed F, Maaz M, Ali US. Soft tissue lasers: An innovative tool enhancing treatment outcomes in orthodontics—A narrative review. *J Pak Med Assoc.* 2023;73(2):346-51.
2. Varma SR, AlShayeb M, Narayanan J, Abuhijleh E, Hadi A, Jaber M, et al. Applications of lasers in refractory periodontitis: A narrative review. *J Int Soc Prev Community Dent.* 2020;10(4):384.
3. Fornaini C, Fekrazad R, Rocca JP, Zhang S, Merigo E. Use of blue and blue-violet lasers in dentistry: A narrative review. *J Lasers Med Sci.* 2021;12:e31.
4. Luchian I, Budalã DG, Baciu ER, Ursu RG, Diaconu-Popa D, Butnaru O, et al. The involvement of photobiology in contemporary dentistry—A narrative review. *Int J Mol Sci.* 2023;24(4):3985.
5. Meghana IS, Bhat AR, Bhandary R, Thomas B. Potential of lasers in the realm of aesthetic dentistry: A narrative review. *J Health Allied Sci NU.* 2022;13(3):313-22.
6. Jahanbin A, Ramazanzadeh B, Ahrari F, Forouzanfar A, Beidokhti M. Effectiveness of Er: YAG laser-aided fiberotomy and low-level laser therapy in

- alleviating relapse of rotated incisors. *Am J Orthod Dentofacial Orthop.* 2014;146(5):565-72. doi:10.1016/j.ajodo.2014.07.006
7. Aras MH, Goregen M, Gungormus M, Akgul HM. Comparison of diode laser and Er: YAG lasers in the treatment of ankyloglossia. *Photomed Laser Surg.* 2010;28(2):173-7. doi:10.1089/pho.2009.2498
 8. Seifi M, Vahid-Dastjerdi E, Ameli N, Badiie M-R, Younessian F, Amdjadi P. The 808 nm laser-assisted surgery as an adjunct to orthodontic treatment of delayed tooth eruption. *J Lasers Med Sci.* 2013;4(2):70.
 9. To TN, Rabie AB, Wong RW, McGrath CP. The adjunct effectiveness of diode laser gingivectomy in maintaining periodontal health during orthodontic treatment. *Angle Orthod.* 2013;83(1):43-7. doi:10.2319/012612-66.1
 10. Ize-Iyamu I, Saheeb B, Edetanlen B. Comparing the 810nm diode laser with conventional surgery in orthodontic soft tissue procedures. *Ghana Med J.* 2014;47(3):107-11.
 11. Aboelsaad N, Attia N. Diode laser treatment of orthodontically induced gingival hyperplasia a randomized controlled clinical trial. *Eur Sci J.* 2013;9(27):107-14.
 12. Sobouti F, Rakhshan V, Chiniforush N, Khatami M. Effects of laser-assisted cosmetic smile lift gingivectomy on postoperative bleeding and pain in fixed orthodontic patients: A controlled clinical trial. *Prog Orthod.* 2014;15(1):66. doi:10.1186/s40510-014-0066-5
 13. Junior RM, Gueiros LA, Silva IH, de Albuquerque Carvalho A, Leao JC. Labial frenectomy with Nd: YAG laser and conventional surgery: A comparative study. *Lasers Med Sci.* 2015;30(2):851-6. doi:10.1007/s10103-013-1461-8
 14. Ahn JH, Power S, Thickett E. Application of the diode laser for soft-tissue surgery in orthodontics: Case series. *J Orthod.* 2021;48(1):82-7.
 15. Demirsoy KK, Kurt G, Waghmare PS, Lakhe P, Daigavane P. Review on orthodontic lasers. *J Pharm Res Int.* 2021;33(60B):2745-52.
 16. Demirsoy KK, Kurt G. Use of laser systems in orthodontics. *Turk J Orthod.* 2020;33(2):133.
 17. Chaturvedi R, Ulla ST, Hussain F, Manzoor Z, Vaid R, Sadiq NU. Different applications of laser in the field of orthodontics: A review. *IP Indian J Orthod Dentofacial Res.* 2021;7(2):90-3.
 18. Shehare NV, Tarvade SM. Laser: A newer tool for orthodontists. *CODS-J Dent.* 2022;13(2):55-7.
 19. Dalvi S, Lingala S, Khetal N, Benedicenti S, Hanna R. Utilisation of an 810 nm diode laser for surgical management of oral soft tissues related to orthodontic treatment: A case series. *J Orthod.* 2022;49(2):221-7.
 20. Amaral Vargas EO, de Melo Magalhães K, Pereira Ferreira DM, Marañón-Vásquez G, Sant'anna EF, Maia LC, et al. Clinical parameters in soft tissue adjunctive periodontal procedures for orthodontic patients: Surgical laser vs scalpel- A systematic review. *Angle Orthod.* 2022;92(2):265-74.
 21. Lazăr AP, Dinulescu T, Dako T, Mărțu MA, Suciuc M, Lazăr L. Laser in periodontology: A review of the fields of applicability and therapeutic effects. *Rom J Oral Rehabil.* 2022;14(1).
 22. Esthetics S. Lasers in orthodontics. Principles and Practice of Laser Dentistry-E-Book. 2022:292.
 23. Shetty SK. Lasers in orthodontics. *Sch J Dent Sci.* 2021;7:224-9.
 24. Dantas CM, Vivan CL, Dominguez GC, de Fantini SM, de Freitas PM. Light in orthodontics: Applications of high-intensity lasers, photobiomodulation, and antimicrobial photodynamic therapies in daily practice. *InPhotonics 2023 Jun 15 (Vol. 10, No. 6, p. 689). MDPI.*
 25. Chmura LG, Convissar RA. Basic laser procedures in orthodontic practice. *InSeminars in Orthodontics 2020 Jun 1 (Vol. 26, No. 2, pp. 80-89). WB Saunders.*